

Management of Mouth Opening in Patients with Temporomandibular Disorders through Low-Level Laser Therapy and Transcutaneous Electrical Neural Stimulation

SILVIA CRISTINA NÚÑEZ, M.Sc.,¹ AGUINALDO SILVA GARCEZ, M.Sc.,¹
SELY SAYURI SUZUKI,² and MARTHA SIMÕES RIBEIRO, Ph.D.¹

ABSTRACT

Objective: The aim of this study was to evaluate the effectiveness of low-level laser therapy (LLLT) and transcutaneous electrical neural stimulation (TENS) on the improvement of mouth opening in patients with temporomandibular disorder (TMD). **Background Data:** TMDs are conditions that affect the form and/or function of the temporomandibular joint (TMJ), masticatory muscles, and dental apparatus. Often TMD is associated with pain localized in the TMJ and/or in the muscles of the face and neck. **Methods:** This clinical trial was performed in 10 patients, 18–56 years old, diagnosed with TMD of multiple causes. All patients received both methods of treatment in two consecutive weeks. LLLT was delivered via a 670-nm diode laser, output power 50 mW, fluence 3 J per site/4 sites (masseter muscle, temporal muscle, mandibular condyle, and intraauricular). TENS therapy was applied with a two-electrode machine at 20 W, maximum frequency of 60 Hz, adjusted by the patient according to their sensitivity. The amplitude of mouth opening was recorded before treatment and immediately after using a millimeter rule; the measurements were performed from the incisal of the upper incisors to the incisal of the lower incisors. A paired *t*-test was applied to verify the significance of the results. **Results:** A significant improvement in the range of motion for both therapies was observed immediately after treatment. Comparing the two methods, the values obtained after LLLT were significantly higher than those obtained after TENS ($p < 0.01$). **Conclusions:** Both methods are effective to improve mouth opening. Comparing the two methods, LLLT was more effective than TENS applications.

INTRODUCTION

TEMPOROMANDIBULAR DISORDER (TMD) is the communal term that describes a number of clinical problems involving the masticatory musculature, the temporomandibular joint, or both. A range of symptoms may be linked to TMD; pain, predominantly in the chewing muscles and/or jaw joint, is the most common symptom. Likely indications of TMD include limited movement or locking of the jaw, radiating pain in the face, neck, or shoulders muscles, painful clicking or grating sounds in the jaw joint when opening or closing the mouth, and a sudden change in occlusal status. Symptoms such as head-

aches, earaches, dizziness, and hearing problems may sometimes be associated with TMD.¹

TMDs fall into three main categories. Myofascial pain is the most common form of TMD. It is characterized by discomfort or pain in the masticatory muscles and sometimes also in the neck and shoulder muscles. The second category is the internal derangement of the joint associated with a dislocated jaw or displaced disc, and an injury to the condyle. Degenerative joint disease is another category, including osteoarthritis or rheumatoid arthritis in the jaw joint.¹

Epidemiological studies show that about 75% of the population present one sign of TMD and 33% present at least one

¹Centro de Lasers e Aplicações, IPEN-CNEN/SP, São Paulo, Brazil.

²Mestrado Profissionalizante em Ortodontia, Centro de Pesquisas Odontológicas–São Leopoldo Mandic, Campinas, Brazil.

symptom. However, only a minor percentage of the population presents problems severe enough to look for treatment for TMD.²

The preliminary management of TMD presumes that primary systemic or overt joint diseases have been identified and addressed.³ A vast array of therapeutic modalities has been offered for TMD patients.² Researchers generally agree that caution is recommended with regard to the use of invasive and irreversible treatments, particularly in the initial management of TMD. A number of noninvasive and reversible therapies appear to help most patients.^{3,4}

The initial management of TMD includes supportive patient education, pharmacologic pain control, and physical therapy—i.e., moist heat, ultrasound, and transcutaneous electrical neural stimulation (TENS).²

TENS is used to relax hyperactive muscles; it acts like a neuromuscular stimulator. TENS equipment produces a low-amplitude, low-frequency alternating stimulus that causes muscles to contract and relax. Applied bilaterally between the temporomandibular joint (TMJ) and the coronoid process, the stimulus reaches the deep mandibular division of the trigeminal nerve, as well as the superficial facial nerve.⁵ This therapy is applied to reduce the muscular activity of masticatory muscles.⁶

Low-level laser therapy (LLLT) seems to be in accordance with TMD's treatment philosophy, because it represents a non-invasive, reversible therapy without any known side effects. LLLT makes use of the electromagnetic radiation of a single wavelength, usually in the red or infrared regions. LLLT provides treatment for several pathologies, including impaired wound healing, pain conditions, and inflammatory situations.^{7,8}

Several reports have documented the positive effects of LLLT in TMD.^{9,10} Kulekcioglu et al.⁹ showed that, after 15 sessions of LLLT, TMD of both myogenic and arthrogenic causes responded to therapy with a significant reduction in pain, improvement in mouth opening and lateral motion, and a diminished number of trigger points. However, the clinical efficacy of LLLT has been questioned.¹¹ Given the large range of treatment parameters involved in this therapy (i.e., wavelength, fluence, intensity, exposure time, total duration of treatment), it is not difficult to understand that results differ from one study to the next.¹²

LLLT, with the appropriate parameters, may act as an analgesic and anti-inflammatory mediator to promote muscle relaxation. According to some reports, LLLT may promote analgesic effects via several mechanisms (e.g., increases liberation of endogenous opiates; decreases permeability of the nerve cell membrane; decreases release of algescic agents in pathological sites; increases ATP production; and decreases tissue asphyxia^{13,14}).

Range of mouth opening is impaired in patients with TMD.¹⁵ Limitation in mouth opening makes access to the oral cavity difficult, leading to complications in the rehabilitative treatment often necessary in patients with TMD. Appropriate access to the oral cavity is necessary to replace missing teeth, to promote occlusal equilibration, or to perform dental impressions to build up removable and functional oral appliances.² These treatments can represent a stressful condition to patients due to the pain provoked by the opening movement.^{16,17}

Therefore, the aim of this work is to evaluate the range of motion of mouth opening in patients with diagnoses of TMD

before and after treatment with LLLT or TENS to observe the clinical effectiveness of each method.

METHODS

The present study involved 10 patients from a private dental office with diagnoses of TMD of multiple causes. Informed consent for participation in this study was obtained in all cases.

Following a preliminary evaluation to exclude patients with systemic disease that could be associated with TMD and overt joint diseases, the inclusion criteria comprised two conditions: limitation of mouth opening due to pain, and not having medical or pharmacological treatment for TMD in the past 6 months.

The patients were 80% female and 20% male. The mean age was 34.4 years (range, 18–56 years). Patients presented multiple causes of TMD, with complaints of pain in the TMJ area. During the study, patients were instructed to not take systemic medication for TMD.

Prior to therapies, the patient was set in a chair with a standard position of 45 degrees between the upper and lower members. The head was supported by a head rest. Patients were instructed to open their mouth until it reached maximum capability without excessive discomfort. With a millimeter ruler, the total mouth opening was recorded, with the measure being performed from the incisal of the upper incisors to the incisal of the lower incisors. Initial values were recorded; all patients received both methods randomly alternated, in one treatment session per week, in 2 consecutive weeks. During the first week, five patients had laser irradiation and five patients had TENS application. After 7 days, the mouth opening was measured as previously described. Thereafter, patients that had LLLT on the previous week got TENS therapy and vice versa.

LLLT was performed with a continuous-wave diode laser (GaAlAs; Kroman, São Paulo, Brazil), emission wavelength of 670 nm, output power of 50 mW for 60 sec, 3 J per site. Four sites were chosen to receive the irradiation: the area over the masseter muscle, over the temporal muscle, over the mandibular condyle, and intra-auricular.¹⁸ The treatment was performed bilaterally with total time duration of 8 min. The intensity was 0.25 W/cm². The laser output power was measured prior to irradiation using a calibrated detector (LaserCheck®, Coherent).

TENS therapy was executed with a two-electrode machine (model hv250r; Hitachi Home Electronics Inc., Japan). The power was 20 W, with a maximum frequency of 60 Hz. The patients were instructed to adjust the intensity of the equipment according to their sensitivity so that the treatment would not be uncomfortable; the equipment has five different intensities. The total duration of the treatment was 30 min. Each electrode was placed in one side, so the treatment was performed bilaterally. The position of the electrode was between the TMJ and the coronoid process, to allow the arrival of the stimulus to the trigeminal nerve, as well as to the facial nerve.

The total aperture measurement was recorded before and immediately after therapies. The results were compared for each individual treatment (before and after treatment values) as well as between treatments (mean of the after treatment improvement).

Statistical analysis

Statistical analyses were accomplished using the paired *t*-test. A *p* value of <0.05 was considered to indicate a statistically significant difference between the groups.

RESULTS

The mean value of the mouth opening amplitude in the group that received TENS in the first week prior to any treatment (*n* = 5) was 35.2 mm (SD = ± 9.9, range [R] = 27). The mean value of the mouth opening amplitude in the group of patients that received LLLT in the first week prior to the treatment (*n* = 5) was 31.4 mm (SD = ± 9.3, R = 23). The mean values of the mouth opening amplitude for the two groups were not significantly different (*p* = 0.55, *t* = 0.49, degrees of freedom [df] = 4).

Figure 1 shows the data for all patients after LLLT. The mean value of mouth opening before LLLT was 34.8 mm (±8.8). Immediately after LLLT, the mean value of mouth opening was 41.7 mm (±6.8). The values after therapy are significantly higher than the initial ones (*p* < 0.01, *t* = 7.66, df = 9).

Figure 2 shows the data for all patients after TENS. The mean value of mouth opening before TENS, was 34.2 mm (±8.9). Immediately after TENS, the mean value of mouth opening was 37.5 mm (±8.3). The amplitude of mouth opening after therapy is significantly higher (*p* < 0.01, *t* = 8.34, df = 9).

After LLLT, the mean value of the increase in mouth opening was 7.2 mm (±2.9). Following TENS, the mean value of the increase in mouth opening was 3.3 mm (±1.2). LLLT was significantly more efficient in improving the mouth opening range of motion compared with TENS (*p* < 0.01, *t* = 4.67, df = 9).

For both groups and treatments, at the end of the first treatment session the mean value of mouth opening (*n* = 10) was 38.8 (±7.99). At the end of the second treatment session, the mean value of mouth opening (*n* = 10) was 40.7 (±7.67). The values at the end of the each week of treatment are not significantly different (*p* = 0.35, *t* = 0.98, df = 9); thus, the beneficial effects were not cumulative.

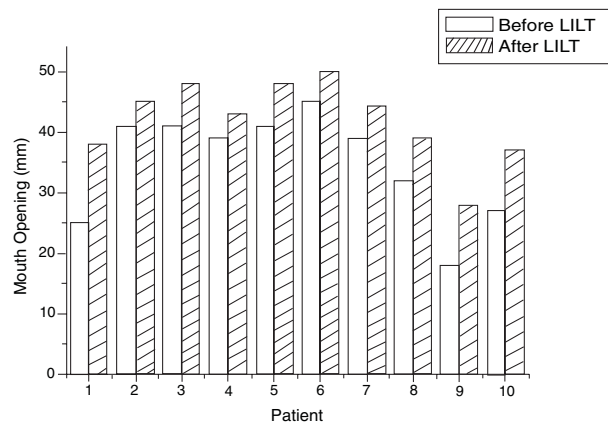


FIG. 1. Mouth opening of patients prior to low-level laser therapy (LLLT) and immediately after therapy.

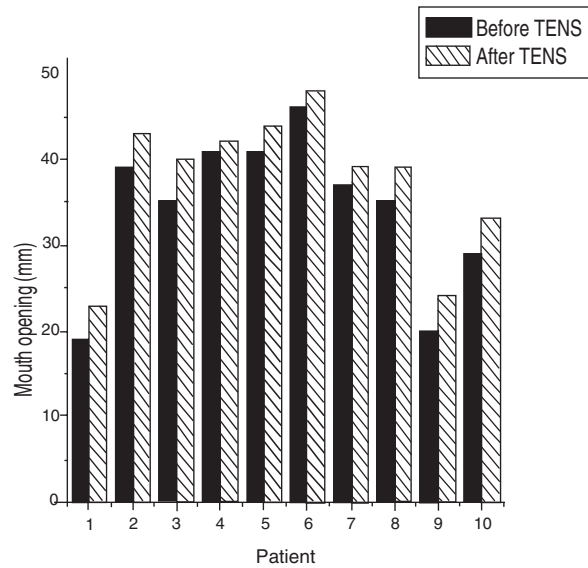


FIG. 2. Mouth opening of patients prior to transcutaneous electrical neural stimulation (TENS) and immediately after therapy.

The initial values compared with the final showed a significant positive increment in the range of mandibular motion in all patients (*p* < 0.001, *t* = 4.71, df = 9).

Figure 3 shows the evolution of the mean of all patients during the studied period. An increase is observed immediately after therapies, although on the 1-week interval between therapies a regression was noted.

Figure 4 presents the data of the patient's evolution during treatment. One group of patients started treatment with LLLT (*n* = 5), which is represented by the first segment of the graphic (initial first week to final first week). During the second week, the same group of patients received TENS, represented by the second segment on the graphic (initial second week to final second week). The second group received exactly the same procedures, starting treatment with TENS instead of LLLT. The evolution of the patients independent of the treatment with which they started is similar (*p* > 0.05, *t* = 2.29, df = 3).

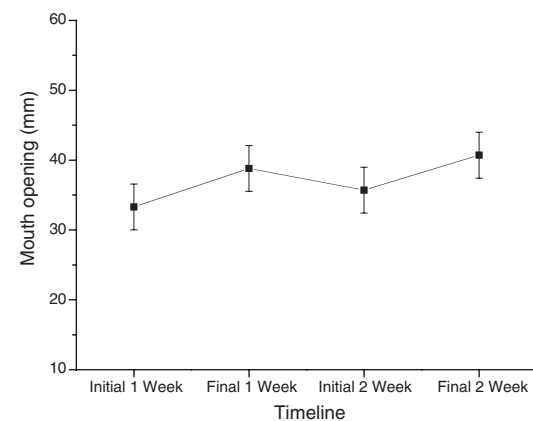


FIG. 3. Mean values ± SD of mouth opening over time.

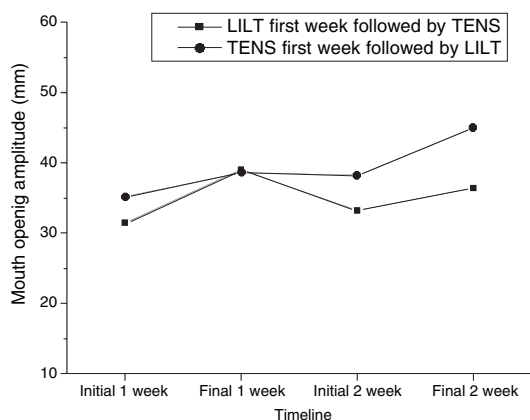


FIG. 4. Mean values of the evolution of mouth opening of both groups during experimental period.

DISCUSSION

In this study, the range of mandibular motion was evaluated in patients with TMD after LLLT or TENS to verify improvement in mouth opening of those patients immediately after therapy. Both therapies were effective in improving the amplitude of mandibular movement. Comparing the two methods, LLLT was more efficient than TENS.

Even though pain is almost certainly the most precise symptom that had been treated in this study, the evaluation of pain, probably, would not be the most objective parameter to assess the purposed treatments. Kulekcioglu et al.⁹ showed that after 15 sessions of LLLT, TMD responded to therapy with a significant reduction in pain presented either by the laser or by the placebo group, but only the active laser group presented improvements on mouth opening, lateral motion, and number of trigger points. So, in this study the range of mandibular motion was chosen to evaluate the efficacy of the purposed treatments.

The psychological component of TMD appears to be remarkably important. Patients with diagnoses of TMD are rendered susceptible to placebo effects of any treatment carried out. Indeed, placebo effect for an assortment of treatments for patients with TMD has been shown to be effective in more than 40% of the cases.^{2,19} In this study, a placebo control was not performed because, although it would be easily achieved in the laser treatment, it would not be performed in the TENS group with the same reliability because the patient would not feel anything and also would not hear a sound for over 30 min; thus, the placebo effect would be compromised by the TENS therapy. Further investigation with a larger sample to investigate placebo effects is warranted.

TENS is conventionally used to relax muscles. TENS therapy is recommended, at a treatment dose of over 60 min.⁵ In order to provide a feasible clinical application, a period of 30 min was chosen. Even with this shorter period of application, TENS therapy was effective in improving the amplitude of mouth opening in a significant manner, although a longer application period could promote even better results.

On the other hand, LLLT has been used to treat a variety of pathological conditions, including musculoskeletal pain, post-traumatic joint disorder, and rheumatoid arthritis.¹³ Although

LLLT has been studied since the early 1960s, it is not established as a clinical tool yet.¹¹ The multitude of parameters involved in this therapy is probably delaying its acceptance in the clinical realm.¹²

Several reports have documented the beneficial effects of LLLT on the management of patients with TMD.^{9–11,20} Gur et al.,²¹ in a randomized controlled, double-blind clinical trial with 60 patients, used the 904-nm laser to treat chronic myofascial pain. The overall result after 2 weeks of treatment showed that LLLT was effective in pain relief and in the improvement of the functional ability of the patients. The energy applied over each site was 3 J. Energies of 6–12 J seem to be effective in promoting muscular relaxation.²⁰

The wavelength used in this work is not considered the most appropriate one to promote analgesic effects due to its penetration depth.²² The radiation penetration depth is a controversial issue, and more objective data about tissue optics are necessary.¹¹ The forward scattering of the radiation would promote the penetration of the radiation into deeper tissues. LLLT's most commonly used wavelengths (630–1300 nm) present a predominant forward-directed scattering.²³ Furthermore, due to the optical characteristic of this therapy, the patient's individual characteristics should also be taken into account, since the right energy does not only have to be applied on the surface, but also must reach the target area.

Both treatments tested in this trial presented good results. LLLT was more efficient than TENS therapy. LLLT is more comfortable to the patient because it does not cause any sensation during its application. TENS therapy promotes a sensation like a minor electrical shock, which is comfortable for some patients while to others is a strange sensation. Thus the patient compliance with the therapy may be an important factor.

The results showed no cumulative beneficial effects because from the end of the first treatment session to the end of the second treatment session no improvements were detected. This data reinforce the probability of an immediately analgesic effect. In patients with TMD, to observe long-lasting improvements, a prolonged treatment may be necessary. In a clinical trial, Conti²⁴ reported that, after three treatment sessions, LLLT with 830-nm laser and energy of 4 J did not show a significant effect. Although some clinical findings were positive, the statistical analyses did not show differences between laser and placebo groups. Conti suggested that increased frequency of laser application may improve the results.²⁴

Randomized, placebo-controlled clinical trials with a significant sample must be performed in order to validate this therapy. The results obtained in this study indicate that LLLT could be an adjuvant in the management of patients with TMD.

CONCLUSION

In this study, the range of mandibular motion was evaluated in patients with TMD after LLLT or TENS to verify improvement in mouth opening immediately after therapy. Both therapies were effective in improving the amplitude of mandibular movement. These treatments should be performed before conventional dental treatment in patients with TMD. Comparing the two methods, LLLT was more effective than TENS therapy.

REFERENCES

1. Friction, J.R. (2004). Temporomandibular muscle and joint disorders. *Pain* 109, 530.
2. Yap, A.U.J., and Ho, V.C.L. (1999). Temporomandibular disorders—an overview. *Singapore Med. J.* 40, 1–6.
3. Blanco, M.M., Bagán, J.V., Fons, A., et al. (2004). Osteoarthritis of the temporomandibular joint. A clinical and radiological study of 16 patients. *Med. Oral.* 9, 106–115.
4. Bradley, P.F. (1987). Conservative treatment for TMJ pain dysfunction. *Br. J. Oral Maxillofacial Surg.* 25, 127–137.
5. Cooper, B.C. (1995). The role of bioelectronic instruments in the management of TMD. *NY State Dent. J.* 61, 48–53.
6. Murphy, G.J. (1997). Physical medicine modalities and trigger point injections in the management of temporomandibular disorders and assessing treatment outcome. *Oral Surg. Oral Med. Oral Pathol. Oral Radiol. Endod.* 83, 118–122.
7. Ferreira, D.M., Zangaro, R.A., Villaverde, A.B., et al. (2005). Analgesic effect of He-Ne (632.8 nm) low-level laser therapy on acute inflammatory pain. *Photomed. Laser Surg.* 23, 177–181.
8. Bayat, M., Vasheghani, M.M., Razavi, N., et al. (2005). Effect of low-level laser therapy on the healing of second-degree burns in rats: a histological and microbiological study. *J. Photochem. Photobiol. B.* 78, 171–177.
9. Kulekcioglu, S., Sivrioglu, K., Ozcan, O., et al. (2003). Effectiveness of low-level laser therapy in temporomandibular disorder. *Scand. J. Rheumatol.* 32, 114–118.
10. Ilbuldu, E., Cakmak, A., Disci, R., et al. (2004). Comparison of laser, dry needling, and placebo laser treatments in myofascial pain syndrome. *Photomed. Laser Surg.* 22, 306–311.
11. Bjordal, J.M., Couppé, C., Chow, R.T., et al. (2003). A systematic review of low level laser therapy with location-specific doses for pain from chronic joint disorders. *Aust. J. Physiother.* 49, 107–116.
12. Núñez, S.C., Nogueira, G.E.C., Ribeiro, M.S., et al. (2004). He-Ne laser effects on blood microcirculation during wound healing: a method of *in vivo* study through laser Doppler flowmetry. *Lasers Surg. Med.* 35, 363–368.
13. Simunovic, Z. (2000). Pain and practical aspects of its management, in: *Lasers in Medicine and Dentistry: Basic Science and Up-to-Date Clinical Applications of Low-Energy-Level Laser Therapy (LLLT)*. Croatia: Vitagraf, pp. 269–300.
14. Walker, J. (1983). Relief from chronic pain by low-power laser irradiation. *Neurosci. Lett.* 43, 339–344.
15. Walker, N., Bohannon, R.W., and Cameron, D. (2000). Discriminant validity of temporomandibular joint range of motion measurements obtained with a ruler. *J. Orthop. Sports. Phys. Ther.* 30, 484–492.
16. Alpern, M.C., Nuelle, D.G., and Wharton, M.C. (1988). TMJ diagnosis and treatment in a multidisciplinary environment follow-up study. *Angle. Orthod.* 58, 101–126.
17. Yap, A.U. (1998). Effects of stabilization appliances on nocturnal parafunctional activities in patients with and without signs of temporomandibular disorders. *J. Oral. Rehabil.* 25, 64–68.
18. Bradley, P., Groth, E., GURSOY, B., et al. (2000). The maxillofacial region: recent research and clinical practice in low-intensity laser therapy (LILT), in: *Lasers in Medicine and Dentistry: Basic Science and Up-to-Date Clinical Applications of Low-Energy-Level Laser Therapy (LLLT)*. Croatia: Vitagraf, pp. 385–402.
19. Dimitroulis, G. (1998). Temporomandibular disorders: a clinical update. *Br. Med. J.* 317, 190–194.
20. Tunér, J., and Hode, L. (2004). Dental laser therapy, in *The Laser Therapy Handbook*. Sweden: Prima Books AB, pp. 208–244.
21. Gur, A., Karakoc, M., Cevik, R., et al. (2003). Efficacy of low power laser therapy and exercise on pain and function in chronic low back pain. *Lasers. Surg. Med.* 32, 233–238.
22. Baxter, G.D. (1994). Low-intensity laser therapy for pain relief, in *Therapeutic Lasers: Theory and Practice*. London: Churchill Livingstone, pp. 139–185.
23. Wilson, B.C., and Jacques, S.L. (1990). Optical reflectance and transmittance of tissues: principles and Applications. *IEEE J. Quant Electron* 26, 2186–2199.
24. Conti, P.C. (1997). Low-level laser therapy in the treatment of temporomandibular disorders (TMD): a double-blind pilot study. *Cranio* 15, 144–149.

Address reprint requests to:

Dr. Silvia Cristina Núñez

Centro de Lasers e Aplicações—IPEN-CNEN/SP

Av. Lineu Prestes, 2242

CEP: 05508-900 São Paulo, SP, Brazil

E-mail: silnunez@aol.com