

# Effect of irradiation with red and infrared laser in the treatment of oral mucositis

A pilot study with patients undergoing chemotherapy with 5-FU

C. B. Cunha · F. P. Eduardo · D. M. Zezell ·  
L. M. Bezinelli · P. P. L. Shitara · L. Correa

Received: 12 November 2011 / Accepted: 15 March 2012  
© Springer-Verlag London Ltd 2012

## Introduction

Oral mucositis (OM) is considered the cause of high morbidity and one of the main side effects of chemotherapy for antineoplastic treatment. The impact of OM on the patient's health ranges from worsening quality of life during chemotherapy through to increased treatment costs [1, 2]. OM refers to lesions of the oral mucosa that vary from erythematous to ulcerative, and may result in various degrees of signs and symptoms, such as burning and pain when swallowing and speaking. These symptoms predispose the patient to nutritional disturbances and ulcerations may increase the risk of opportunistic infections [2].

The drug 5-fluorouracil (5-FU) is an antimetabolite that works on the S-phase of the cell cycle, promoting DNA

damage. It is used as a chemotherapeutic agent in the therapy of control and remission of various solid tumors, such as those of the gastrointestinal tract, breast and cervix. Its adverse effects are conditioned to the form of administration and dose, and involve hematologic, dermatologic and gastrointestinal tract alterations. In the latter, OM is one of the first and most severe complications generated by 5-FU therapy, followed by diarrhea, which may be considered a clinical manifestation of intestinal mucositis. In 5-FU therapy, patients of the female gender [3] and advanced age have been associated with greater risk for the occurrence of OM, which is manifested in a larger number of patients between the third and seventh weeks after infusion of the drug, and can persist up to the 24th week in patients with gastrointestinal tract tumors [4].

Various treatment modalities have been used for chemotherapy-induced OM, among them therapy with growth factors for keratinocytes, anti-inflammatory drugs with benzidamin, natural agents such as aloe vera and camomile, and physical agents as cryotherapy and laser therapy [5, 6]. There is evidence in the literature that low level laser therapy in OM lesions results in significant reduction of its severity [7, 8], and promotes an important preventive effect on the appearance of lesions [9]. The beneficial effects of laser irradiation on conditions of mucositis involve both aspects of injury repair and analgesia. In the latter case, frequently the reduction in painful symptomatology in the oral cavity, even where there are ulcerations, facilitates chewing and ingestion of foods, which helps to maintain the patient's nutritional levels and quality of life.

In general, the majority of present irradiation protocols involve the use of red laser in the selected wavelength of 660 nm, ranging between 632.8 and 685 nm [10]. These types of lasers are mainly characterized by their reparative

---

C. B. Cunha  
Aristides Maltez Hospital,  
Salvador, BA, Brazil

F. P. Eduardo (✉) · L. M. Bezinelli  
Hospital Israelita Albert Einstein,  
São Paulo, SP, Brazil  
e-mail: fpeduard@usp.br

D. M. Zezell  
IPEN/CNEN,  
São Paulo, SP, Brazil

P. P. L. Shitara  
Sorocaba Hospital Joint,  
Sorocaba, SP, Brazil

L. Correa  
School of Dentistry,  
University of São Paulo,  
São Paulo, SP, Brazil

effect by stimulating fibroblast, endothelial and epithelial cell proliferation [11, 12]. They also have an immediate and effective analgesic effect on pain control [13].

Lasers emitting light in the infrared region have seldom been used to control OM. The cited studies mainly describe the use of laser at a wavelength of 780 and 830 nm (GaAIAs) [9, 14]. In addition to influencing the repair process, these lasers are outstanding mainly because they generate a mediate and more prolonged analgesic effect [13]. To the best of our knowledge, no studies were found in the literature, in which there was an association of red (660 nm) and infrared (780 nm) lasers as therapy for the control of OM.

The aim of this study was to verify the efficacy of 660 nm laser associated with 780 nm laser in reducing the severity of OM, and the impact of this reduction on the eating habits and satisfaction of the patient. The hypothesis would be that this association would bring greater benefits than the treatment with 660 nm laser only, particularly considering the prolonged analgesic effects of 780 nm laser.

## Patients and methods

The Research Ethics Committee of “Hospital Aristides Maltez” – Salvador, BA, Brazil, approved the following methodology. This was a case descriptive, prospective blind study.

### Patients

A total of 62 patients undergoing chemotherapy treatment, with OM were examined, and the following inclusion criteria were applied: currently undergoing endovenous infusion chemotherapy of 5-FU without combination with other chemotherapeutic agents; must be 18 years or older; during oral examination, present one or more regions exhibiting lesions indicative of OM, both in the initial (erythema only) and in the ulceration stage. The following patients were excluded: those with a previous and current history of radiotherapy in the oral cavity; with chronic diseases associated with the primary tumor (e.g., diabetes and AIDS), and those who had had previous treatment or were undergoing treatment for OM. This selection was made by a calibrated operator to clinically identify the different aspects of OM. With these criteria, 18 patients were selected, with whom two interviews were held: one before beginning the treatments for OM, and the other after these therapies. In the first interview information was collected about gender, age, base disease, chemotherapy regimen, presence of smoking and drinking habits, history of diabetes and leukogram data and number of platelets in the last hematological exam. In addition, the

types of food ingested (whether solid, pasty and liquid) were researched, in both the first and second interviews.

The oral health status was evaluated at the time of the first interview, when the physical exam of the oral cavity was performed, observing the oral hygiene status and presence of infectious foci such as caries, gingivitis, periodontal disease or endodontic problems. In this consultation, patients received guidance as regards oral hygiene and the use of extra soft tooth brushes (Curaden-curaprox®, CS 5460 prime). After this they were divided into three groups, with six patients each: Control Group (CG) — without the use of laser therapy for control of OM; Group irradiated with laser emitting light in the red region — with laser therapy using 660 nm laser for the treatment of OM; Group irradiated with laser emitting light in the red region and immediately afterwards, with laser emitting light in the infrared region — with laser therapy combining 660 nm laser with a sequential phase of 780 nm laser.

### Treatments for OM

The patients in the CG were prescribed to use mouthwashes twice a day (in the morning and at night) with 0.12 % chlorhexidine without alcohol, for 5 days. They were instructed to perform the mouthwash for around 1 min, 30 min after mouth brushing, and not to drink water afterwards for a period of 20 min.

The patients in red laser group were submitted to five daily session of low level laser irradiation. The equipment used was a diode laser (Twin Laser – MM Optics S.A ou Ltda., São Carlos, SP, Brazil) emitting a 660-nm wavelength ( $\lambda$ ), set at an output power of 30 mW, with beam area of 0.04 cm<sup>2</sup> in the focal region. The laser beam from a InGaAlP semiconductor was delivered by a fiber optic and used in the point radiation mode and in contact with the mucosa for 10 s per point, resulting in a calculated energy density of 7.5 J/cm<sup>2</sup>. Each point in the irradiated area was at a distance of about 1 cm from the other irradiation points. These were disposed on the lesions suggestive of OM, such as the inferior and superior labial mucosa, bilateral jugal mucosa and the right and left lateral edges of the tongue [10].

The patients in red laser plus infrared laser group were submitted to five daily sessions of laser irradiation with association of the two wavelengths in sequence (first  $\lambda$ = 660 nm and afterwards,  $\lambda$ =780 nm). The laser beams were delivered by two independent fibers in a single device consisting of an InGaAlP (660 nm) and a GaAlAs (780 nm) diode laser. The equipment used was a diode laser (Twin Laser – MM Optics S.A ou Ltda.) set at an output power of 15 mW, with beam area of 0.04 cm<sup>2</sup> in the focal region. They were used in the point radiation mode and in contact with the mucosa for 10 s per point, resulting in a calculated energy density of 3.8 J/cm<sup>2</sup>. Each point in the irradiated area

was at a distance of about 1 cm from the other points, with the same regions being irradiated as described for red laser group.

In each laser irradiation procedure, the principles of biosafety were applied, i.e., use of laser protective eyewear, gloves and masks, as well as covering the laser tip with PVC film. The same operator always performed laser irradiation procedure.

#### Evaluation of treatments

Signs and symptoms of OM were monitored before treatments and after five treatment sessions. The oral mucosa was examined by a dental surgeon to assess the degree of mucositis, which was classified according to the system validated by Monopoli et al. [15] and applied by Vera-Llonch et al. [1]. This system is based on the following grading: 0, absence of sites with erythema, ulceration or pseudomembrane; 1=presence of erythema and absence of ulceration; 2=presence of erythema, ulceration or pseudomembrane affecting only one site; 3=presence of erythema, ulceration or pseudomembrane affecting two sites; 4=presence of erythema, ulceration or pseudomembrane affecting three sites; 5=presence of erythema, ulceration or pseudomembrane affecting more than three sites.

On a daily basis, during the 5 days of evaluation, a visual scale was also applied to evaluate patient satisfaction with the results of treatment. This scale was created and validated especially for this research because, at the time of selecting the patients it was found that they had difficulties with interpreting written or other visual scales and filling out questionnaires, due to their low level of schooling. Thus, a simpler visual scale was applied, containing only icons representative of satisfaction: ☺ — SATISFIED; I feel no pain; I am able to eat better, I can speak better; I am satisfied; I like the treatment; ☹ — DISSATISFIED; I feel pain, I cannot eat, I cannot speak; I am not satisfied; I don't like the treatment.

#### Statistical analysis

Descriptive statistical analysis was performed by means of Fisher's exact test. For numerical variables, the Kruskal–Wallis and Mann–Whitney tests were used. The level of significance adopted was 5 %.

## Results

The 18 selected patients were submitted to chemotherapy with 5-FU in daily doses according to total body surface area, infused endovenously for approximately 2 h, on 5 consecutive days. Table 1 exhibits the medical and dental data of the analyzed patients. The majority of patients were men (12/18, 66.7 %) in all groups. The median age was 47.5

in control, 62.5 in red laser group and 53.0 in red laser plus infrared laser group, with a minimum age of 41 years and a maximum of 90 years. There were frequent smokers and ex-smokers (13/18), and absence of drinking habits (15/18). The majority of primary tumors of patients originated in the digestive system, oropharyngeal carcinoma being most frequent (8/18, 83.3 % in red laser and 33.3 in red laser plus infrared laser group), followed by carcinoma of the colon (3/18, 16.7 % in the CG and 33.3 % in red laser plus infrared laser group). The mean number of leukocytes in the overall count was maintained within the reference values from 3,600 to 11,000 leukocytes/mm<sup>3</sup> in all groups with the lowest mean in red laser plus infrared laser group (4,005±3,135/mm<sup>3</sup>). In platelet counts, the lowest mean was also observed in red laser plus infrared laser group (216.1±100.7×10<sup>3</sup>/mm<sup>3</sup>); however, all groups exhibited values within the reference limits of 130 to 400×10<sup>3</sup>/mm<sup>3</sup>. The majority of patients exhibited no dental caries (7/16 did have caries), however, periodontal disease was detected with high frequency (15/18). Only in the variable “primary tumor” was there a statistically significant difference among the three groups.

Table 2 contains the frequencies of the degrees of OM before and after treatments. It can be observed that before treatments, in all groups, the majority of patients had mucositis grade I (5/6 in control and 3/6 in red laser and red laser plus infrared laser groups). After treatments, in the CG there was reduction in the frequency of Grade 1 patients (3/6) and presence of two Grade 0 patients; however, in one patient mucositis developed to Grade V. In the red laser group, an improvement was noted in one of the two patients who had grade IV, and the presence of a patient with grade 0, not observed previously; the patient who had grade V before laser irradiation, remained in this condition. Significant improvement was observed after treatment in red laser plus infrared laser group, with increased frequency of grade I (4/5) and grade 0 (2/6) and absence of patients with grades II to V. Table 3 shows the results of the statistical tests applied to pairs of groups. It is noted that before treatments there were no statistically significant differences when the groups were crossed. However, after the treatments, red laser group and red laser plus infrared laser group presented statistically significant differences in comparison with the CG ( $p=0.0190$ ). Figure 1 illustrates the status of oral mucosa in each of the groups.

Table 4 presents the frequencies of patients according to the consistency of food ingested before and after treatments. One observes that 1/6 patient in the CG, 3/6 in the red laser group and 5/6 in the red laser plus infrared laser group ingested only liquids or pasty foods at the beginning of treatment. No statistically significant differences were detected among the groups before treatments ( $p=0.074$ ). After treatments, in the CG there were no changes in consistency of the foods ingested ( $p=0.600$ ). In the red laser

**Table 1** Medical and dental data of patients undergoing chemotherapy with 5-fluorouracil, with oral mucositis

	Control group (n=6)	Red laser group (n=6)	Red and infrared laser group (n=6)	p Value control×lasers
Gender, n (%)				
Male	4 (66.7)	4 (66.7)	4 (66.7)	1.00
Female	2 (33.3)	2 (33.3)	2 (33.3)	
Age, median (range)	47.5 (41–72)	62.5 (44–90)	53 (47–74)	0.257
Smoking, n (%)				
Non smoker	0(0.0)	2(33.3)	3(50.0)	
Smoker	3(50.0)	2(33.3)	1(16.7)	0.206
Ex-smoker	3(50.0)	2(33.3)	2(33.3)	
Alcoholism, n (%)				
Yes	1(16.7)	1(16.7)	1(16.7)	1.00
No	5 (83.3)	5 (83.3)	5 (83.3)	
Nasogastric probe, n (%)				
Yes	1(16.7)	3(50.0)	0(0.0)	0.250
No	5 (83.3)	3 (50.0)	6 (100.0)	
Primary tumor, n (%)				
Oropharyngeal carcinoma	0 (0.0)	5 (83.3)	3 (50.0)	
Esophageal carcinoma	1 (16.7)	0 (0.0)	1 (16.7)	
Maxillary sinus carcinoma	1 (16.7)	0 (0.0)	0 (0.0)	0.009
Gastric carcinoma	1 (16.7)	0 (0.0)	2 (33.3)	
Colon carcinoma	1 (16.7)	0 (0.0)	0 (0.0)	
Colonrectal carcinoma	1 (16.7)	0 (0.0)	0 (0.0)	
Rectal carcinoma	1 (16.7)	0 (0.0)	0 (0.0)	
Breast carcinoma	0 (0.0)	1 (16.7)	0 (0.0)	
Hematological data (mean ± SD)				
Total leukocytes/mm <sup>3</sup>	7,390±3,618	6,040±2,264	4,005±3,135	0.142
Platelets (×10 <sup>3</sup> /mm <sup>3</sup> )	266.0±79.25	354.6±142.2	216.1±100.7	0.297
Caries, n (%)				
Yes	2 (33.3)	3 (50.0)	2 (33.3)	1.00
No	4 (66.7)	3 (50.0)	4 (66.7)	
Periodontal disease, n (%)				
Yes	6 (100.0)	5 (83.3)	4 (66.7)	0.735
No	0 (0.0)	1 (16.7)	2 (33.3)	

Statistically significant when  $p < 0.05$

group, one could say there was an improvement in the eating pattern (4/6 and 2/6 patients began to ingest liquid/pasty or solid foods, respectively), since it was not impossible for any

of the patients to eat after laser irradiation, whereas before there were 2/6 patients with difficulties for eating. Nevertheless, these differences were not statistically significant

**Table 2** Frequency of patients according to the degree of oral mucositis before and after the treatments instituted

Oral mucositis <sup>a</sup>	Control group (n=6) (%)		Red laser group (n=6) (%)		Red and infrared laser group (n=6) (%)	
	Before	After	Before	After	Before	After
Grade 0	0 (0.0)	2 (33.3)	0 (0.0)	1 (16.7)	0 (0.0)	2 (33.3)
Grade I	5 (83.3)	3 (50.0)	3 (50.0)	1 (16.7)	3 (50.0)	4 (66.7)
Grade II	0 (0.0)	0 (0.0)	0 (0.0)	1 (16.7)	1 (16.7)	0 (0.0)
Grade III	0 (0.0)	0 (0.0)	0 (0.0)	1 (16.7)	0 (0.0)	0 (0.0)
Grade IV	1 (16.7)	0 (0.0)	2 (33.3)	1 (16.7)	1 (16.7)	0 (0.0)
Grade V	0 (0.0)	1 (16.7)	1 (16.7)	1 (16.7)	1 (16.7)	0 (0.0)

<sup>a</sup>Vera-Llonch et al. [1]

**Table 3** *z*- and *p*-Values for the crossed pairs in the Mann–Whitney test with reference to the oral mucositis scores attributed before and after treatments

Crossing between groups	Oral mucositis before treatments	Oral mucositis after treatments
Control versus red laser	$z=1.146, p=0.2516$	$z=-2.345, p=0.0190$
Control versus red and infrared laser	$z=1.146, p=0.2518$	$z=-2.345, p=0.0190$
Red laser versus red and infrared laser	$z=-0.086, p=0.9316$	$z=0.000, p=1.0000$

Significant when  $p<0.05$

( $p=0.067$ ). In the red laser plus infrared laser group, there were significant changes in the consistency of the foods ingested ( $p<0.001$ ), in which 5/6 patients began to ingest solid foods, and none found it impossible to eat after laser irradiation.

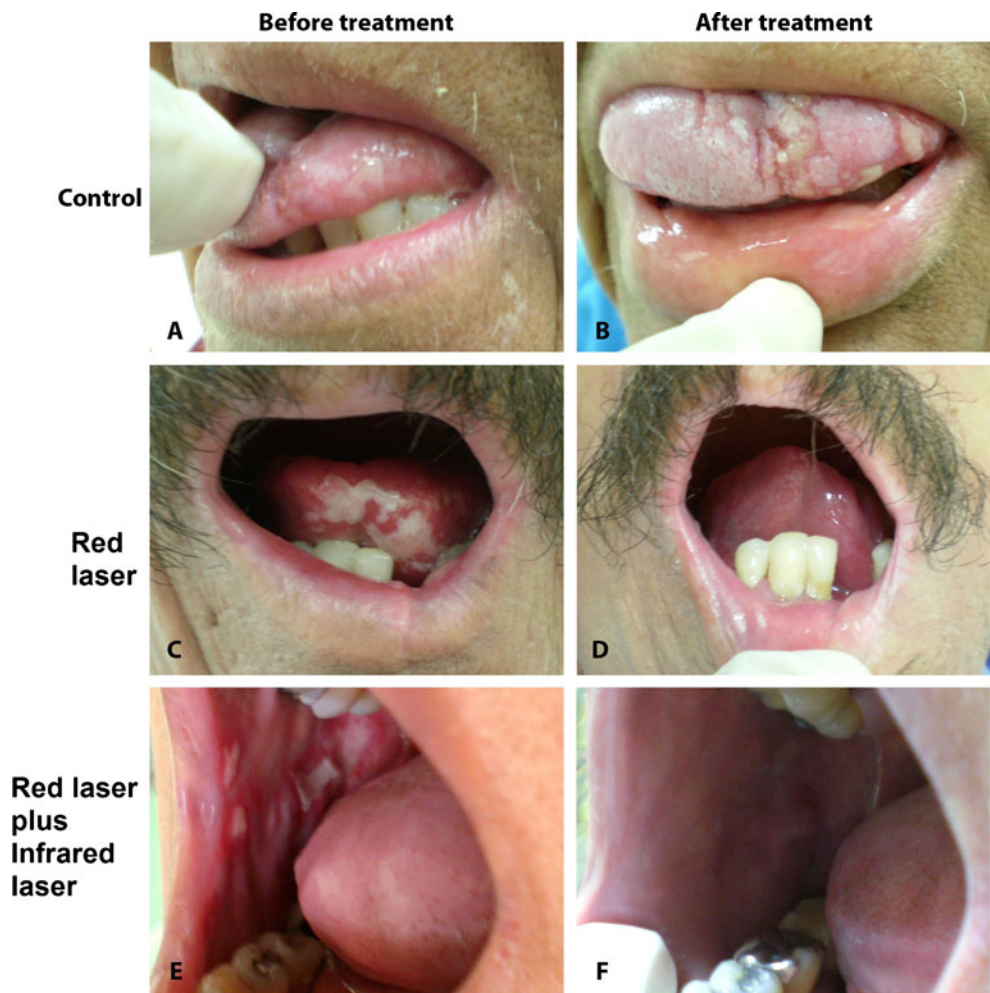
Figure 2 illustrates the frequencies of satisfied patients at the beginning and end of treatment. On the first day, none of the patients were satisfied with their oral condition. On the second day of attendance, one notes that only patients in the groups with laser therapy (2/6 in both red laser group and red laser plus infrared laser group) were shown to be satisfied. Only from the third day onwards, one patient in the CG exhibited satisfaction, which increased slightly on the fourth and fifth days (2/6 patients). Patients' satisfaction with laser therapy was constant on the fourth and fifth days, with all patients satisfied with their oral condition. Statistical analysis

shows there were statistically significant differences between the initial and final evaluation performed by patients with regard to red laser group and red laser plus infrared laser groups (for both,  $p<0.001$ ), but no statistically significant differences were observed when evaluating the degree of initial and final satisfaction for the CG ( $p=0.491$ ).

## Discussion

The aim of this pilot study was to verify the influence of laser therapy with laser light emission in the red region alone or combined with a sequential phase with laser light emission in the infrared region on the symptomatology and degree of severity of OM induced by 5-FU. The main result

**Fig. 1** Examples of oral mucositis lesions in patients undergoing chemotherapy with 5-FU, according to three experimental groups, before and after treatment instituted. **a** and **b** OM lesion on lateral edge of tongue, which developed into more widespread ulcerations in the lingual mucosa after 5 days of follow-up. **c** and **d** Extensive lesion, with pseudomembrane and areas of ulceration in the lingual mucosa, which exhibits improvement after irradiation with red laser. **e** and **f** Multiple mucositis lesions in the jugal mucosa, which also exhibit reduction in severity after 5 days of irradiation with red laser associated with infrared laser



**Table 4** Frequency of patients according to the type of food for each group analyzed

Consistency of food	Control group ( <i>n</i> =6) (%)			Red laser group ( <i>n</i> =6) (%)			Red and infrared laser group ( <i>n</i> =6) (%)		
	Before	After	<i>p</i>	Before	After	<i>p</i>	Before	After	PE
Impossibility of eating	1 (16.7)	1 (16.7)		2 (33.3)	0 (0.0)		1 (16.7)	0 (0.0)	
Liquid/pasty	1 (16.7)	1 (16.7)	0.600	3 (50.0)	4 (66.7)	0.067	5 (83.3)	1 (16.7)	<0.001
Solid	4 (66.7)	4 (66.7)		1 (16.7)	2 (33.3)		0 (0.0)	5 (83.3)	

Fisher's exact test. Significant when  $p < 0.05$

of this study was that the combination of the two wavelengths of laser irradiation caused reduction in the degrees of OM, as well as leading to significant improvement in eating pattern.

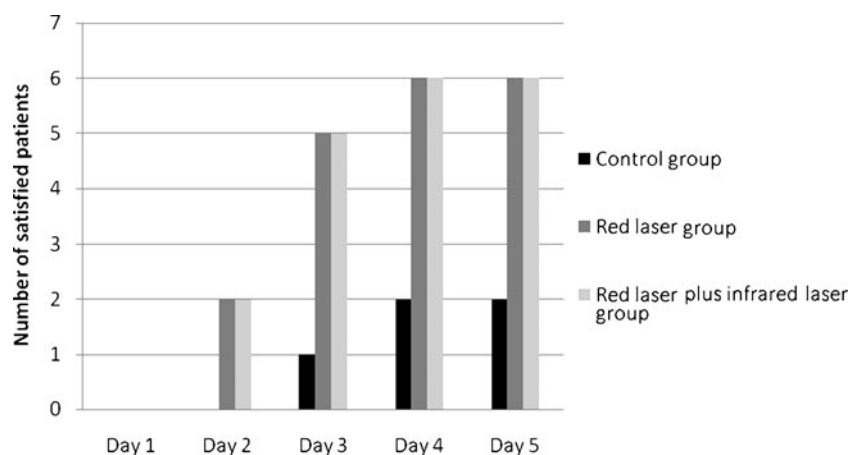
In this study, in addition to the improved repair of lesions, the combination of the two lasers probably resulted in a more intense and prolonged analgesic effect, which facilitated the ingestion of solid foods. Low-level laser in the infrared spectrum (with a wavelength of over 700 nm) has better penetration into tissue (between 3 and 5 cm), than red laser (between 600 and 700 nm, penetrating 2–5 mm), in spite of also being absorbed in the more superficial regions [16]. As OM involves the loss of epithelial continuity due to inflammatory signaling in the lamina propria [17], one could say that irradiation of the two lasers amplified the therapeutic window [16], comprising both the papillary region of the lamina propria subjacent to the epithelium, the reticular region a little further from the epithelial surface, and the submucosa. This must have led to a significant reduction in the severity of OM in red laser plus infrared laser group, to an even greater extent than in red laser group. As regards analgesia, there is a certain consensus among studies that low-level lasers generate an analgesic effect [18], which may arise from various mechanisms. A recent review on the analgesic effects of low level laser therapy demonstrated that both red and infrared laser lead to a reduction in nerve conduction velocity, inhibition of A $\delta$  and C fibers, and impairment on the release of nociceptive substances and chemical mediators of algogens, such as bradykinine and prostaglandin E<sub>2</sub> [13]. Association between the two lasers must

have amplified the area of interference in the sensitive nervous system, comprising not only superficial peripheral nerve endings, but also the nerves located close to the submucosa. As this study was limited to identifying the clinical aspect of OM lesions only, and the symptomatology of the patients reported in a subjective manner, it is difficult to be precise about the causes in the improvement of the eating pattern generated by the association of the two lasers. Further studies are necessary to verify the mechanisms for the inhibition of algogens obtained with this association and the real effects of this inhibition on the eating pattern of patients.

Studies have demonstrated that infrared laser alone also led to positive results in the control of OM. A study with children undergoing chemotherapy demonstrated that irradiation for 5 consecutive days with 830 nm laser (100 mW, 4 J/cm<sup>2</sup>) significantly diminished the duration of OM lesions in comparison with the placebo group [14]. Similar results were also found in another research with children with OM, also using 830 nm laser (140 mW) [19]. On the other hand, in another study the preventive effect of red (650 nm) and infrared (780 nm) laser was tested on OM induced by high doses of chemotherapy in bone transplant patients. The energy density used for irradiation with both lasers was 2 J/cm<sup>2</sup> up to the second day after the transplant. Reduction in pain in the oral cavity and severity of OM was observed significantly in the group irradiated with red laser [9].

Although there was statistically significant differences between control and red laser group concerning OM scores,

**Fig. 2** Number of patients satisfied with the treatment for oral mucositis during 5 days of follow-up for 5-FU chemotherapy



it was not possible to identify a clear reduction on the severity of OM lesions in the group irradiated only with red laser. The OM frequencies in this group after the laser treatment exhibited a different distribution in the various degrees, including IV and V grades. This fact contradicts other findings in the literature that affirm that there was a reduction in severity and duration of OM lesions [8, 20, 21]. The low number of patients, as well as following up the development of these lesions in a short space of time probably had an influence on this result. Nevertheless, in spite of the reduced size of the sample, it could be concluded that red laser changed the pattern of severity of the lesions, as there was greater frequency of patients with grade 0 and less frequency of those with grade IV. Enlargement of the sample and longer follow-up time is crucial in order to confirm this reduction in the severity of OM with these types of lasers.

There was also a change in the pattern of severity of OM lesions in the CG treated only with chlorhexidine mouthwash. There is consensus that chlorhexidine is not an effective and specific treatment for OM [22]; nevertheless, it can be used to help with oral hygiene in immunosuppressed patients. In this study it was observed that mouthwash with chlorhexidine contributed to improving the index of the number of sites affected by OM in some patients, however, it did not lead to satisfaction with treatment, probably because it did not reduce the painful symptomatology. Furthermore, two patients who had difficulty in ingesting solid foods did not present an improvement in eating pattern.

It is worth saying that the results of the efficacy of treatment are based mainly on the classification of OM, which was based on the criterion of the number of sites affected. In view of this, the results of this study may not be comparable with those that use other grading systems. The classification applied by Vera-Llonch et al. [1] was adopted because it was considered more appropriate for evaluating the reduction in and repair of lesions. Other classifications, such as that of the WHO, include the difficulties with eating in the grading, which partly make them more subjective, as they depend on the patients report and the institution of therapeutic nutritional measures, among them peripheral parenteral nutrition. As this nutritional aspect in the present study was analyzed by means of another scale, which included interviews with the patient and data collection from record charts, it was considered better to adopt a more objective grading system for the clinical aspects of OM.

Monitored cleaning of the oral cavity in all patients for the control of OM severity was crucial for the results obtained. There is consensus that control and treatment of OM must be accompanied by oral care, which appears to contribute directly to the reduction in the time of duration of OM induced by chemotherapy [23]. Thus, the positive results of laser therapy, and even in the CG, in the control

of OM are also derived from careful oral hygiene and infectious foci elimination.

An important characteristic of the present study is that it included patients undergoing chemotherapy exclusively with 5-FU, without being associated with other chemotherapies. Therapy with 5-FU is considered high risk for OM, since it has an important cytotoxic effect on digestive tract cells. Specific measures for the prevention of OM for patients undergoing chemotherapy with 5-FU have been recommended, such as oral cryotherapy during endovenous infusion of the drug [22, 24]. Ischemia arising from the reduction in temperature of the oral mucosa appears to reduce contact of the drug with the cells of these tissues, diminishing its local toxic effect. Thus, the association of cryotherapy as a preventive measure with laser as a curative measure of OM lesions appears to be promising for the broader control of OM.

In conclusion, the association of irradiation with laser light emission in the red region with infrared for the treatment of OM induced by 5-FU was efficacious in reducing the severity of these lesions and led to improvement in the eating pattern of patients. In view of these positive effects, it is recommendable that a broader based study should be conducted, with a larger number of patients, and a more prolonged follow-up period, in order to establish a more specific protocol for this association.

**Conflicts of interest** The authors declare that there are no conflicts of interest in this report.

## References

- Vera-Llonch M, Oster G, Ford CM, Lu J, Sonis S (2007) Oral mucositis and autologous hematopoietic stem-cell transplantation following high-dose melphalan conditioning for multiple myeloma. *Supportive Oncol* 5:231–235
- Elting LS, Keefe DM, Sonis ST, Garden AS, Spijkervet FK, Barash A, Tishler RB, Canty TP, Kudrimoti MK, Vera-Llonch M (2008) Burden of illness Head and Neck writing committee. Patient-reported measurements of oral mucositis in head and neck cancer patients treated with radiotherapy with or without chemotherapy demonstration of increased frequency, severity, resistance to palliation, and impact on quality of life. *Cancer* 113(10):2704–2713
- Chansky K, Benedetti J, Macdonald JS (2005) Differences between men and women treated with 5-fluoracil therapy for colorectal carcinoma. *Cancer Care* 15(6):1665–1671
- Tebbutt NC, Norman AR, Cunningham D, Allen M, Chau I, Oates J, Hill M (2003) Analysis of the time course and prognostic factors determining toxicity due to infused fluorouracil. *Br J Cancer* 19;88(10):1510–1515
- Alterio D, Jereczek-Fossa BA, Fiore MR, Piperno G, Nassarin M, Orechia R (2007) Cancer treatment-induced oral mucositis. *Anti-cancer Res* 27:1105–1126

6. Clarkson JE, Worthington HV, Furness S, McCabe M, Khalid T, Meyer S (2010) Interventions for treating oral mucositis for patients with cancer receiving treatment. *Cochrane Database Syst Rev* 4(8):CD001973
7. Bensadoun RJ (2006) Low level LASER therapy (LLLT): a new paradigm in the management of cancer therapy-induced mucositis. *Indian J Med Res* 124:375–378
8. Antunes HS, Azevedo AM, Silva-Bouzas LF (2009) Low-power laser in the preventions of induces oral mucositis in the bone transplantation patients: a randomized trial. *Blood* 109:225–255
9. Schubert MM, Eduardo FP, Guthrie KA, Franquin JC, Bensadoun RJ, Migliorati CA, Lloid CM, Eduardo CP, Walter NF, Marques MM, Hamdi M (2007) A phase III randomized double-blind placebo-controlled clinical trial to determine the efficacy of low level laser therapy for the prevention of oral mucositis in patients undergoing hematopoietic cell transplantation. *Support Care Cancer* 15(10):1145–1154
10. Eduardo FP, Bezinelli L, Luiz AC, Correa L, Vogel C, Eduardo CP (2008) Severity of oral mucositis in Patients undergoing Hematopoietic Cell transplantation and an oral laser Phototherapy protocol: a survey of 30 patients. *Photomed Laser Surg* 26:1–7
11. Lopes NNF, Plaper M, Chavantes MC, Lalla RV, Yoshimura EM, Alves MTS (2009) Cyclooxygenase-2 and vascular endothelial factor expression in 5-fluoracil-induced oral mucositis in hamsters: evaluation of two low-intensity laser protocols. *Support Care Cancer* 17(11):1409–1415
12. França CM, Nunez SC, Prates RA, Noborikawa E, Faria RM, Ribeiro MS (2009) Low-intensity red laser on the prevention and treatment of induced-oral mucositis in hamsters. *J Photochem Photobiol B* 94:25–31
13. Chow R, Armati P, Laakso EL, Bjordal JM, Baxter GD (2011) Inhibitory effects of laser irradiation on peripheral mammalian nerves and relevance to analgesic effects: a systematic review. *Photomed Laser Surg* 29:365–381.
14. Kuhn A, Porto FA, Miraglia P, Brunetto AL (2009) Low-level infrared laser therapy in chemotherapy-induced oral mucositis: a randomized placebo-controlled trial in children. *J Pediatr Hematol Oncol* 31(1):33–37
15. Monopoli M, Woo S, Valley M, Sonis S. A site-based scoring system of chemotherapy-induced oral mucositis in bone marrow transplant recipients. Presented at the Sixth Annual Meeting of the Society of Oral Oncology. Keystone, CO; August 1, 1991. Abstract
16. Enwemeka CS (2009) Intricacies of dose in laser phototherapy for tissue repair and pain relief. *Photomed Laser Surg* 27(3):387–393
17. Sonis ST (2010) New thoughts on the initiation of mucositis. *Oral Dis* 16(7):597–600
18. Reddy GK (2004) Photobiological basis and clinical role of low-intensity lasers in biology and medicine. *J Clin Laser Med Surg* 22(2):141–150
19. Cauwels RG, Martens LC (2011) Low level laser therapy in oral mucositis: a pilot study. *Eur Arch Paediatr Dent* 12(2):118–123
20. Arora H, Pai KM, Maiya A, Vidyasagar MS, Rajeev A. Efficacy of He–Ne Laser in the prevention and treatment of radiotherapy-induced oral mucositis in oral cancer patients. *Oral Surg Oral Med Oral Pathol Oral Radiol Endod* 2008 105(2):180–186, 186.e1
21. Silva GB, Mendonça EF, Bariani C, Antunes HS, Silva MA (2011) The prevention of induced oral mucositis with low-level laser therapy in bone marrow transplantation patients: a randomized clinical trial. *Photomed Laser Surg* 29(1):27–31
22. Raber-Durlacher JE, Elad S, Barach A (2010) Oral mucositis—review. *Oral Oncol* 46:452–456
23. Santos PSS, Coracin FL, Barros JC, Dullely FL, Nunes FD, Magalhães MG (2010) Impact of oral care prior to HSCT on the severity and clinical outcomes of oral mucositis. *Clin Transplant* 10:1–4
24. Papadeas E, Naxakis S, Riga M (2007) Prevention of 5-fluorouracil — related stomatitis by oral cryotherapy: a randomized controlled study. *Eur J Oncol Nurs* 11:60–65